



Surgical Closure of Oroantral Communication by Buccal Fat Pad Flap

Kalakhy Younes*

Oral Surgery Department, Targa Dental Clinic, Marrakech City Kingdom of Morocco

***Corresponding Author:** Kalakhy Younes, Oral Surgery Department, Targa Dental Clinic, Marrakech City Kingdom of Morocco.

DOI: 10.31080/ASDS.2022.06.1345

Received: February 02, 2022

Published: March 25, 2022

© All rights are reserved by **Kalakhy Younes.**

Abstract

The accidental opening of the sinus cavity to the oral cavity is not uncommon during tooth extraction, a tumor process, ballistic trauma or any intervention in the posterior maxillary sector; considered a real oral emergency. where the management of closing this breach between the sinus and the oral cavity is necessary in order to avoid the risk of sinusitis with all its complications by passage of germs from the oral cavity to the sinus.

The diagnostic process is based on clinical and radiological examination to identify and confirm communication on the one hand and measure the extent of the breach and assess bone resorption in order to indicate the appropriate treatment protocol.

Therapeutic management is based on the principle of closing the gap between the oral compartment and the sinus compartment, several solutions can be undertaken depending on the degree of communication and bone loss, among the reliable tools in the hands of the surgeon is the displacement the buccal fat pad to close the gap.

The aim of this paper is to present two clinical cases about oro antral communication treated by a buccal fat pad flap.

Keywords: Oro Antral Communication; Oral Fistulae; Buccal Fat Pad; Sinus

Abbreviations

BFP: Buccal Fat Pad; OAC: Oro-Antral Communication

Introduction

The oro-antral communication (OAC) is an unnatural communication between oral cavity and the sinus, the main reason of this cases in the upper posterior aeria is the anatomical proximity between upper premolar and molar roots with the sinus floor and sometimes we find the roots projected into the sinus cavity [1,2].

Now the question is how to manage this complication?

The first procedure is to check the OAC dimension, generally the defect which are smaller than 2mm can be heal spontaneously by the blood clot, however in the large bone defect cases more than 4mm, the early management of the opening the sinus cavity to the

oral cavity should be undertaken because sinusitis presents the major complication according to several authors as wasmund(60%), on the other hand when the communication has not closed and healed spontaneously, an fistulae is formed and it's a epithelialization of mucosae, generally this epithelialization usually occurs when the perforation persists for at least 48 - 72 hours [3].

The principal of the management by the practitioner is the closure of the OAC, basically variable therapeutic modalities have been described in scientific literature in order to manage OAC cases as coronally advanced flap, bone graft, PRF, Implant; among all this tools the clinician could use the buccal fat pad (Table 1).

The buccal fat pad (BFP)

The BFP is a mass of fatty tissue, stays in deep facial space especially in the masticatory space. Heister was the first to describe

the BFP structure in 1732 as a glandular tissue, in 1802 the French anatomist Xavier Bichat (figure 1) described accurately the anatomical structure, however Egyedi in 1977 used the BFP as pedicled graft for closure of the OAC [4,5].

In fact, the BFP is used in several indications [5] in oral and maxillofacial surgery field

- In tumoral surgery by the reparation of the tissue defect following the tumors excision
- Cleft palatal surgery
- Coverage of bone graft
- TMJ arthroplasty

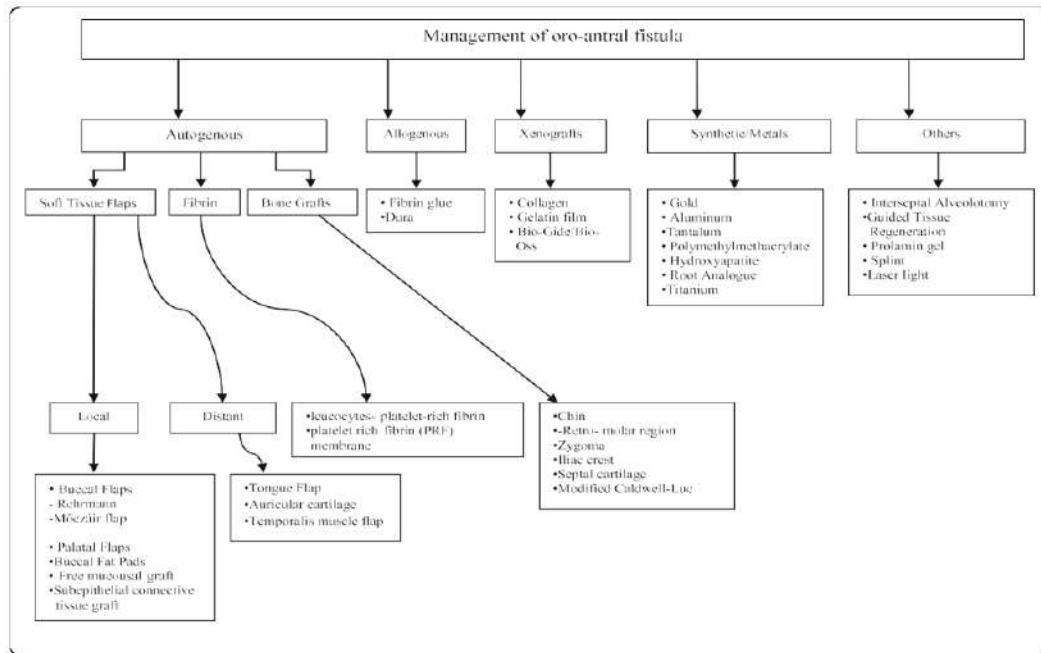


Table 1: Management of oro antral fistulae logarithm by Puria Parvini, Karina Obreja [14].



Figure 1: The French anatomist Xavier Bichat.

(https://www.larousse.fr/encyclopedie/personnage/Marie_Fran%C3%A7ois_Xavier_Bichat/108843)

Anatomy (Figure 2)

The BFP is a lobule mass located within masticatory space behind the zygomatic arch, basically formed by a main body and four extensions according of each anatomical aeria: buccal, pterygoid, pterygopalatine and temporal.

The vascularization supply is derived from 3 branches of the maxillary artery: deep temporal, buccal and the posterior superior alveolar artery, additional blood supply is derived from branches of facial artery, in the other hand the venous drainage is provided by the facial vein [6,7].

The buccal fat pad flap (Figure 3)

The principal

The first principal should treat the sinusitis if it's occurring after opening the oral cavity on the sinus, secondly the fistulae should be

removed with a good and acute of the sinus floor, finally ensure the closure and hermeticity of the sinus cavity

Surgical protocol [10-13]

Since Egyedy and Tideman when the buccal fat pad flat was described in order to close the OAC, this surgical technique as very popular by the oral and maxilla facial worldwide, the main advantage of this technique is facility to perform, his low rate of complication and morbidity, ensure immediate closure, and well accepted by our patients.

Basically, the steps of surgical protocol are

- Local anesthesia
- A full thickness flap is raised with a first intrasulcular incision on the ridge or surrounding the OAC, however we could also made two releasing incisions in the mesial and the distal side according to a trapezoidal flap (a).
- In the muco gingival junction, the flap is dissected delicately with the dean scissors until the BFP, the assistant also could apply downward pressure on the cheek skin above the zygomatic arch (b).
- The tissues surrounding the BFP is delicately cut and we coronally tow the BFP and it is positioned on the ridge (b).
- The BFP is sutured with two plans, the first between the lingual flap and BFP and secondly by the mucco periosteal flap and the same lingual flap (c).

Case report 1

Patient information

A healthy 23 years was referred from her otorhinolaryngologist for an OAC on left side to our oral surgery department, the patient presented a sinusitis treated by her otorhinolaryngologic doctor and occurred after left second molar extraction in a dental office in the city

Clinical examination findings

The clinical exam did notice the presence of a fistulae on the ridge (Figure4),

The radiographic findings (Figure 5)

On the jaw scanner, we could notice the OAC with a bone defect.

The goals of treatment were

- Remove the fistulae
- Close the communication between each compartment oral and sinus cavity

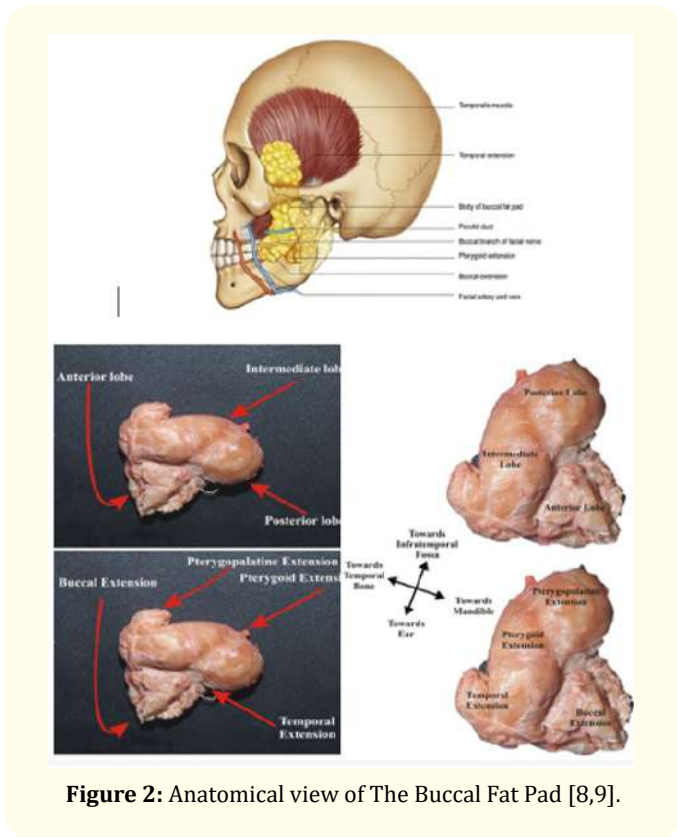


Figure 2: Anatomical view of The Buccal Fat Pad [8,9].

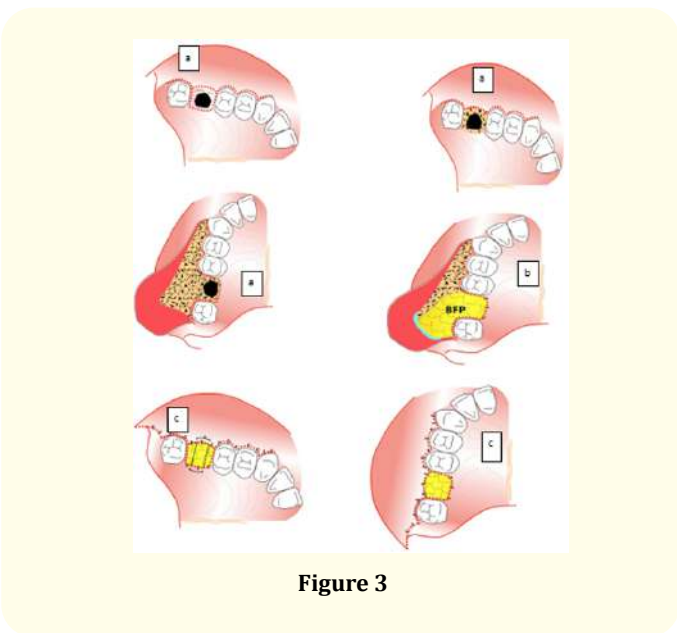


Figure 3

- Ensure the hermeticity of sinus cavity
- Prevent the sinus infection

The treatment plans curettage of the fistulae and the closure of the OAC by the buccal fat pad flap.

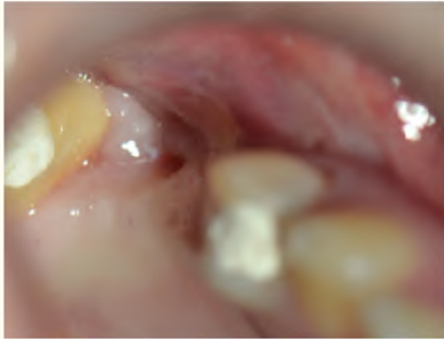


Figure 4: The fistulae on ridge on intra oral view.

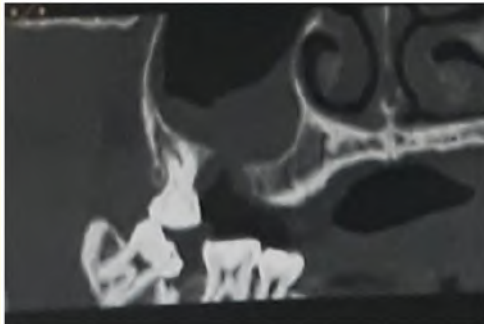


Figure 5: On the jaw scanner exam we notice the bone defect of the OAC.

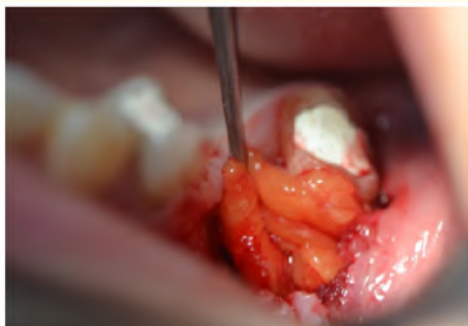

Figure 6: Intraoral view of exposure of the BFD.

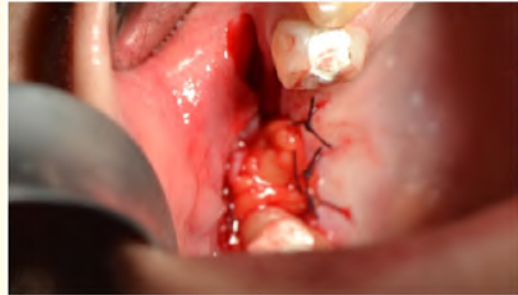

Figure 7: Suture of the BFD on the lingual mucosae.

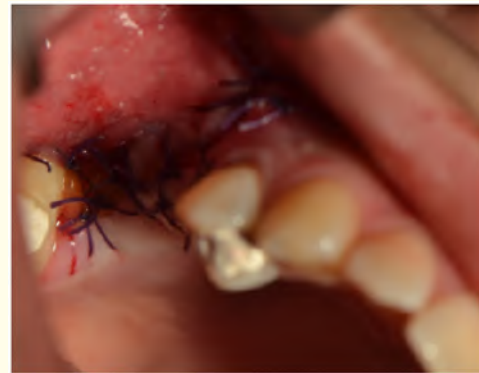

Figure 8: Hermeticity is ensured by a coronally advanced flap.

Case report 2

Patient information

A healthy man 50 years was referred from his dental surgeon for an oro antral communication on left side to our oral surgery department, the patient presented a sinusitis treated by her otorhinolaryngologic doctor and occurred after left first upper molar extraction.

Clinical examination findings

(Figure 9-12)

Surgical protocol (Figure 12)

- Surgical site disinfection by povidone iodine (a)
- Horizontal incision on the ridge and two releasing incisions on the mesial and distal side followed by a curettage of the fistulae (b)

- A mucco periosteal flap is made until the muco-gingival junction (c)
- With a chisel, we make an incision around muco-gingival junction until exposure the BFP (d)
- The BFP is delicately advanced coronally and sutured in the lingual mucosae(d)
- The mucco periosteal flap is coronally advanced and sutured by a simple o point (e,f)
- Epithelialization of surgical site after 10 days (g)

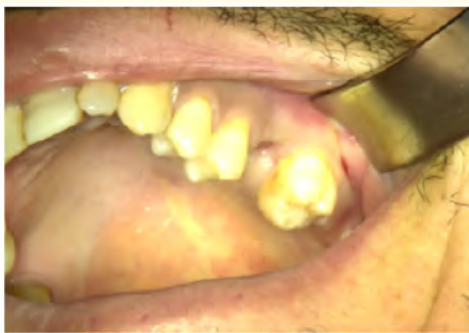

Figure 9: The preoperative view showed the mucosal fistulae after first upper left molar extraction.

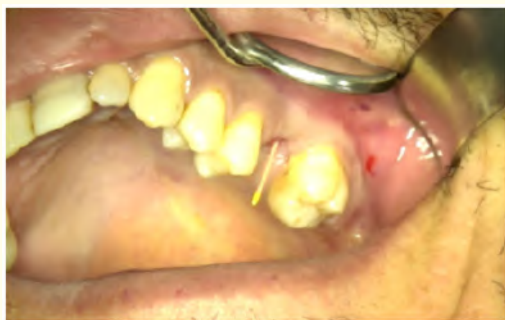

Figure 10: X ray preparation for the exploration of the oro antral communication by a gutta-percha cone.

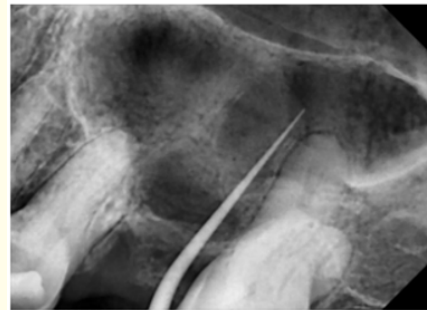

Figure 11: Long cone paralleling technic x ray exploration showed that the gutta percha goes into the sinus cavity, so we confirm the oro antral communication.

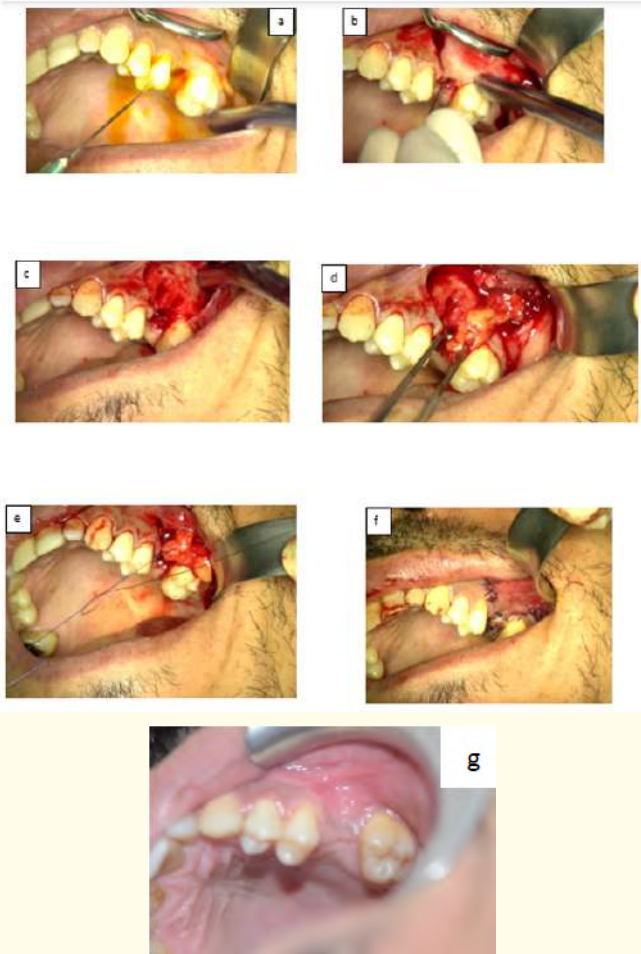


Figure 12: Surgical protocol of OAC by BFP.

Discussion

The OAC might occur frequently in daily practice, above all the anatomical relationship between the posterior molar teeth and the sinus floor situations [14].

The main goal of treatment plan is ensuring the surgical closure of the communication between oral and sinus cavity compartment, the clinical and radiographical exam is important in order to define precisely the dimension communication, presence of the mucosae fistulae and the sinusitis considered of the main complication of the OAC.

Generally, the OAC smaller than 5mm is closed by the buccal fat pad flap, this surgical technique is now well documented in scientific literature and has a good result [15], even if the literature review showed the presence of an insufficient number of randomized clinical studies and also studies with small samples [24].

The BFP as previously described is an anatomical structure firstly described by the French anatomist Xavier Bichat in 1802, but her use as surgical closure of OAC cases has described by Egyedi in 1977, in addition the indications of BFP have extended to several pathological situation as: jaw cancer surgery, plastic surgery, surgery of temporomandibular joint [5].

the technique is now standardized in clinical practice worldwide, the main advantages are: simplicity, convenient, low morbidity and anatomical risks, low complication rate, no visible scare and well accepted by the patient. However, the most disadvantage is the limitation of a small defect [16].

In our clinical experience, the results remain acceptable if the indication is well thought out and the surgical protocol is well respected, the greatest advantage that we have noticed is the simplicity and the low morbidity and the thickness of the mucosa obtained compared to coronally advanced flap alone, its main drawback is her limitations exist concerning the potential size of the defects to be covered.

Conclusion

From the data cited above, we could conclude that in OAC cases, the buccal fat flap remains a reliable tool, especially in cases of small bone defect well demonstrated by the literature review. however, a clinical and radiological evaluation is necessary to pose the

indication, the success of the case is conditioned by the respect of the surgical protocol.

Bibliography

1. J Thomas Lambrecht. "Les communications bucco-sinusiennes". *Rev Mens Suisse Odontostomatol* 108 (1998).
2. Yechen Gu., et al. "Evaluation of the relationship between maxillary posterior teeth and the maxillary sinus floor using cone-beam computed tomography". *BMC Oral Health* 18 (2018): 164.
3. Kani Bilginaylar. "Comparison of the Clinical Outcomes of Buccal Advancement Flap Versus Platelet-Rich Fibrin Application for the Immediate Closure of Acute Oroantral Communications". *Journal of Craniofacial Surgery* 30.1 (2019): e45-e49.
4. Morgann TIBI. "La Boule de Bichat et ses utilisations en Chirurgie Orale". *Année* (2013).
5. Giuditta Mannella Francesco Arcurib. "Buccal Fat Pad: Report of 24 Cases and Literature Review of 1,635 Cases of Oral Defect Reconstruction". *ORL: Journal for Oto-Rhino-Laryngology and its Related Specialties* 81 (2019): 24-35.
6. Yun-Ta Tsai and Yajie Zhang. "The Surgical Anatomy and the Deep Plane Thread Lift of the Buccal Fat Pad". *Plastic and Reconstructive Surgery - Global Open* 8.6 (2020): e2839.
7. Hai -Ming Zhang and Yi-Ping Yan. "Anatomical structure of the buccal fat pad and its clinical adaptations". *Plastic and Reconstructive Surgery* 109.7 (2002).
8. Paul scott., et al. "The Buccal Fat Pad in the Closure of Oro-Antral Communications: An Illustrated Guide". *Dental Update* (2004).
9. Saad Yousuf., et al. "A review of the gross an Surg Radiol Anat anatomy, functions, pathology, and clinical uses of the buccal fat pad". *Surgical and Radiologic Anatomy* 32 (2010): 427-436.
10. Paul W., et al. "Closure of Oroantral Communications with Bichat's Buccal Fat Pad American Association of Oral and Maxillofacial Surgeons". *Journal of Oral and Maxillofacial Surgery* 67 (2009): 1460-1466.
11. Pasquale Procacci and Fortunato Alfonsi. "Surgical Treatment of Oroantral Communications". *The Journal of Craniofacial Surgery* 27.5 (2016).
12. Puria Parvini and Karina Obreja. "Surgical options in oroantral fistula management: a narrative review". *International Journal of Implant Dentistry* 4 (2018): 40.

13. Pulkit Khandelwal and Neha Hajira. "Management of Oro-antral Communication and Fistula: Various Surgical Options". *World Journal of Plastic Surgery* 6.1 (2017).
14. Woo-Sung Son and Yong-Il Kim. "Anatomical relationship between the maxillary posterior teeth and the sinus floor according to an anterior overbite". *Orthodontics and Craniofacial Research* 23.2 (2019).
15. Kiran Kumar Krishanappa S and Prashanti E. "Interventions for treating oro-antral communications and fistulae due to dental procedures (Review)". *Cochrane Database of Systematic Reviews* 5 (2016).
16. Fairouz Chouikh. "The Buccal Fat Oral Pad Flap". *Oral and Maxillofacial Surgery Clinics of North America* 33 (2021): 177-184.
17. Borja Franco-Carro and Cristina Barona-Dorado. "Meta-analytic study on the frequency and treatment of oral antral communications". *Medicina Oral, Patología Oral y Cirugía Bucal* 16.5 (2011): e682-687.
18. Stefano Andrea Denes and Riccardo Tieghi. "The Buccal Fat Pad for Closure of Oroantral Communication". *The Journal of Craniofacial Surgery* 27.3 (2016).
19. Joe Iwanaga and Charlotte Wilson. "Clinical anatomy of the maxillary sinus: application to sinus floor augmentation". *Anatomy and Cell Biology* 52 (2019): 17-24.
20. Gustavo Bravo Cordero and Simona Minzer Ferrer y Lara Fernández. "Sinusitis odontogénica, fístula oroantral y su reparación quirúrgica mediante colgajo de bolsa de Bichat: revisión de la literatura". *Acta Otorrinolaringológica Española* (2015).
21. Sung Hyun Kang and Bom Sahn Kim. "Proximity of Posterior Teeth to the Maxillary Sinus and Buccal Bone Thickness: A Biometric Assessment Using Cone-beam Computed Tomography". *Journal of Endodontics* 41.11 (2015): 1839-1846.
22. Michał Kapustecki and Wona Niedzielska. "Alternative method to treat oroantral communication and fistula with autogenous bone graft and platelet rich fibrin". *Medicina Oral, Patología Oral y Cirugía Bucal* 21.5 (2016).
23. Wei Cheong Ngeow. "The use of bichat's buccal fat pad to close oroantral communications in irradiated maxilla". *Journal of Chirurgie Maxillo-Faciale Buccale* 68.1 (2010): 229-230.
24. Susan H Visscher and Baucke van Minnen. "Closure of Oroantral Communications: A Review of the Literature". *Journal of Oral and Maxillofacial Surgery* 68 (2010): 1384-1391.
25. Mahamadou Konate, et al. "Management of Oroantral Fistulae and Communications: Our Recommendations for Routine Practice". *Case Reports in Dentistry* (2021): 6.
26. Nina Von Wowern. "Frequency of oro-antral fistulae after perforation to the maxillary sinus". *Scandinavian Journal of Dental Research* 78 (1970): 394-396.

Assets from publication with us

- Prompt Acknowledgement after receiving the article
- Thorough Double blinded peer review
- Rapid Publication
- Issue of Publication Certificate
- High visibility of your Published work

Website: www.actascientific.com/

Submit Article: www.actascientific.com/submission.php

Email us: editor@actascientific.com

Contact us: +91 9182824667